



Foot Rot in Grazing Cattle

John G. Kirkpatrick, DVM
Associate professor Medicine and Surgery

David Lalman, PhD
Extension Beef Cattle Specialist

Oklahoma Cooperative Extension Fact Sheets
are also available on our website at:
<http://osufacts.okstate.edu>

Foot rot is a subacute or acute necrotic (decaying) infectious disease of cattle, causing swelling and lameness in one or more feet. The disease can become chronic, with a poorer prognosis for recovery if treatment is delayed, which results in deeper structures of the toe becoming affected. Weight gain is significantly reduced when grazing cattle contract the disease. In one three-year study, Brazle (1993) reported that affected steers gained 2.3 lbs. per day, while steers not affected gained 2.76 lbs. per day. Foot rot is usually sporadic in occurrence, but the disease incidence may increase up to 25% in high-intensity beef or dairy production units. Approximately 20% of all diagnosed lameness in cattle is actually foot rot.

Cause

Mechanical injury or softening and thinning of the interdigital (between the toes) skin by puncture wounds or continuous exposure to wet conditions are necessary to provide entrance points for infectious agents. *Fusobacterium necrophorum* is the bacterium most often isolated from infected feet, but is also frequently isolated from non-diseased interdigital skin. The majority of *F. necrophorum* isolated belong to biotypes A and AB which produce toxins that cause necrosis (decay) of the infected tissues. *F. necrophorum* is also isolated from liver abscesses in feeder cattle, necrotic stomatitis in calves, and calf diphtheria. *F. necrophorum* appears to act cooperatively with other bacteria, such as *Bacillus melaninogenicus*, *Staphylococcus aureus*, *Escherichia coli*, and *Actinomyces pyogenes*, thereby decreasing the infective dose of *F. necrophorum* necessary to cause disease. *Bacteroides nodosus*, the organism causing foot rot in sheep, may cause an interdigital skin surface infection in cattle, allowing entrance of *F. necrophorum* and thereby causing foot rot.

Transmission

Feet infected with *F. necrophorum* serve as the source of infection for other cattle by contaminating the environment. Disagreement exists on the length of time *F. necrophorum* can survive off of the animal, but estimates range from one to ten months. Once loss of skin integrity occurs, bacteria gain entrance into subcutaneous tissues and begin rapid multiplication and production of toxins that stimulate further continued bacterial multiplication and penetration of infection into the deeper structures of the foot.

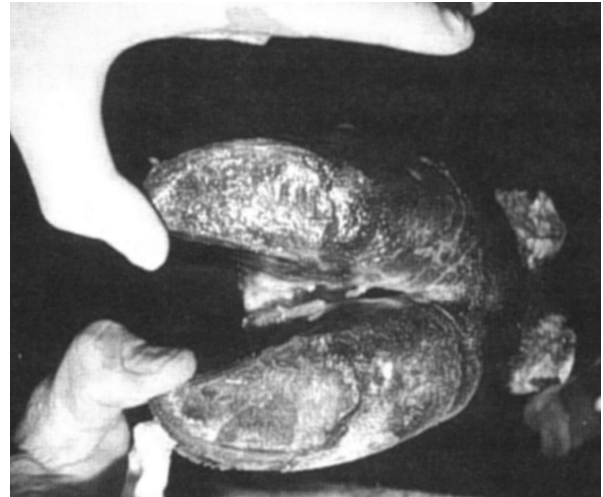

Figure 1. Foot rot in a cow showing separation of the interdigital skin, revealing a whitish-yellow necrotic core-like material.

Clinical signs

Foot rot occurs in all ages of cattle, with increased case incidence during wet, humid conditions. When case incidence increases in hot and dry conditions, attention must be directed to loafing areas, which are often crowded and extremely wet from urine and feces deposited in small shaded areas. The first signs of foot rot, following an incubation period of five to seven days, are lameness, acute swelling of interdigital tissues, and swelling evenly distributed around the hairline of both hooves. Eventually the interdigital skin cracks open, revealing a foul-smelling, necrotic, core-like material (Figure 1). Untreated, the swelling may progress up the foot to the fetlock or higher. More importantly, the swelling may invade the deeper structures of the foot such as the navicular bone, coffin joint, coffin bone, and tendons.

"Super foot rot," seen in some areas of the country, has received this name due to the rapid progression of symptoms, severity of tissue damage, and lack of response to standard treatments. There is reported response to Naxcel® as an effective treatment. The standard footbaths have not been effective in preventing the disease.

Diagnosis

Diagnosis of foot rot can be made by a thorough examination of the foot, looking at the characteristic signs of sudden onset of lameness (usually in one limb), elevated body temperature, interdigital swelling, and separation of the interdigital skin. Other conditions causing lameness and affecting the foot that may be confused with foot rot are: interdigital dermatitis, sole ulcers, sole abscesses, sole abrasions, infected corns, fractures, septic arthritis, and inflammation or infection of tendons and tendon sheaths, all of which often only involve one claw of the foot.

Digital dermatitis (hairy heel warts) is often confused with foot rot because of foot swelling and severity of lameness. Digital dermatitis affects only the skin, beginning in the area of the heel bulbs and progressing up to the area of the dewclaws; whereas, foot rot lesions occur in the interdigital area and invade the subcutaneous tissues. Cattle grazing endophyte infected fescue pastures that develop fescue toxicity, causing loss of blood circulation to the feet and subsequent lameness, are sometimes mistaken as having foot rot.

Treatment

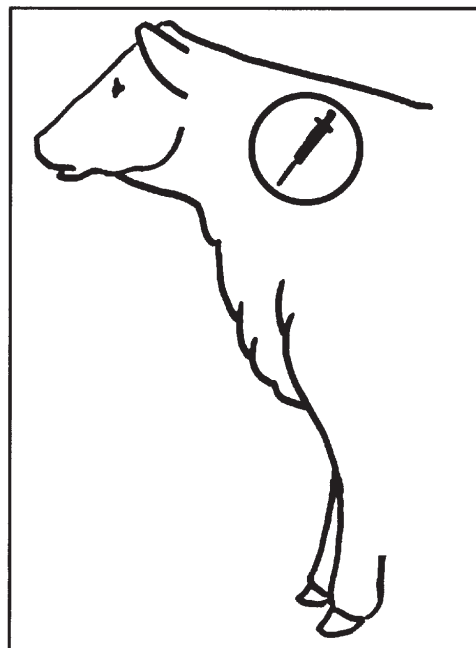
Treatment of foot rot is usually successful, especially when instituted early in the disease course. Treatment should always begin with cleaning and examining the foot to establish that lameness is actually due to foot rot. At this time, a topical treatment of your choice should be applied. Some very mild cases will respond to topical therapy only. Most cases require the use of systemic antimicrobial therapy. LA 200[®], Bio-Mycin 200[®], Procaine penicillin G, Tylan 200[®], and Sustain III[™] (sustained release Sulfamethazine) boluses are over the counter pharmaceuticals that have proven effective as a treatment of foot rot. Naxcel[®], Micotil[®], and Albon S.R.[®] (sustained release Sulfadimethoxine) boluses are antimicrobials restricted to the use by the order of a licensed veterinarian, and have also shown to be effective in the treatment of foot rot. Your veterinarian may deem it necessary to use or oversee the use of one of these restricted drugs as a treatment for non-responding cases.

If at all possible, affected animals should be kept in dry areas until healed. If improvement is not evident within three to four days, it may mean the infection has invaded the deeper tissues. Infections that do not respond to initial treatments need to be re-evaluated by your veterinarian in a timely manner. He or she will want to determine if re-cleaning, removing all infected tissue, application of a topical antimicrobial, and bandaging are appropriate, along with an antimicrobial change. In the more severe cases, management of the animal will be between salvaging for slaughter (following drug withdrawal times), claw amputation, or in valuable animals, claw-salvaging surgical procedures. Your veterinarian will be able to provide you with information you may need in making this decision.

Prevention

Preventive measures are centered on the prevention of mechanical damage to the foot as caused by frozen or dried mud, brush-hogged weeds or brush, stubble, and minimizing the time cattle must spend standing in wet areas.

- Follow all label directions.
- Administer all drugs labeled for intramuscular (IM) use in the muscle of the neck only.
- Administer all drugs labeled for subcutaneous (SubQ) use under the skin of the neck or behind the shoulder.
- Always use SubQ labeled drugs when possible.
- Do not give more than 10 ml in one IM site.
- Re-check all drug withdrawal times with your veterinarian.
- A veterinary - client - patient relationship needs to be in place for the use of all prescription drugs and drugs used off-label (at dosages and for purposes other than defined on the label).



Other preventive measures presently used include the use of footbaths (most often used in confinement beef or dairy operations), feeding low levels of chlortetracycline, addition of organic and inorganic zinc to the feed or mineral mixes, and vaccination.

Foot baths:

Zinc sulfate - 10%	Copper sulfate - 10%
16 lbs. per 20 gallons water	16 lbs. per 20 gallons water
Treat 1 - 2 times weekly	Treat 1 - 2 times weekly
Keep clean	Beware of toxicity in sheep
	Keep clean

Low level feeding of chlortetracycline (CTC) is labeled through the Food and Drug Administration for beef cattle, for the reduction of liver abscesses at 70 mg per head per day. *F. necrophorum* is the major infective agent in liver abscesses and foot rot in cattle. CTC is labeled at 350 mg per head per day (at least 0.5 mg per lb. per day) in beef cattle under 700 lbs., and 0.5 mg per lb. per day in cattle over 700 lbs., for the prevention of anaplasmosis. Consequently, many mineral mixes and commercial supplements are formulated to provide

350 mg per head per day, to control those diseases listed on the CTC label. Since foot rot is caused by the same organism as liver abscesses, some control of foot rot should occur at the 350 mg per head per day level. Due to the difficulty in conducting studies for a disease with low incidence, large controlled comparative studies evaluating the effectiveness of continually feeding CTC to grazing stocker cattle have not been reported. Most research trials indicate that average daily gain is increased in grazing cattle by .1 to .3 lbs. when CTC is included in a free choice mineral mix in grazing cattle. Keep in mind, there is no label use for CTC in lactating dairy cattle due to milk residue problems.

When cattle are moderately to severely deficient in dietary zinc, supplemental zinc may reduce the incidence of foot rot. Zinc is important in maintaining skin and hoof integrity; therefore, adequate dietary zinc should be provided to help minimize foot rot and other types of lameness. In a three-year study, zinc methionine added to a free-choice mineral supplement reduced the incidence of foot rot and improved daily weight gain in steers grazing early summer pasture (Table 1).

A commercial vaccine approved for use in cattle as a control for foot rot is available. Reported results by producers and veterinarians have been mixed from their use of this product, and controlled studies have not been reported. Your veterinarian, by knowing your specific geographic area, will be able to assist you in initiating preventive measures for foot rot.

Summary

Foot rot is one of many conditions of the foot that cause lameness in cattle. For treatment to be effective it must be started early in the course of the disease. It is necessary to have a break in skin integrity for foot rot to occur. The most important preventive measures are centered on the protection of interdigital skin health.

Table 1. The effect of zinc methionine in a mineral mixture on gain and incidence of foot rot on steers grazing native pastures^a.

Ingredient	Zinc Methionine	Control
Number of steers	342	354
Starting wt., lbs.	583	587
Daily gain, 93 days, lbs.	2.79 ^a	2.71 ^b
Incidence of foot rot, %	2.45 ^a	5.38 ^b
Daily mineral intake, lbs.	.24	.22
Daily zinc methionine intake, g.	5.4	-

^a Brazle, F.K. 1993. Cattlemen's Day Report of Progress 704. Agriculture Experiment Station. Kansas State University.

The Oklahoma Cooperative Extension Service

Bringing the University to You!

The Cooperative Extension Service is the largest, most successful informal educational organization in the world. It is a nationwide system funded and guided by a partnership of federal, state, and local governments that delivers information to help people help themselves through the land-grant university system.

Extension carries out programs in the broad categories of agriculture, natural resources and environment; family and consumer sciences; 4-H and other youth; and community resource development. Extension staff members live and work among the people they serve to help stimulate and educate Americans to plan ahead and cope with their problems.

Some characteristics of the Cooperative Extension system are:

- The federal, state, and local governments cooperatively share in its financial support and program direction.
- It is administered by the land-grant university as designated by the state legislature through an Extension director.
- Extension programs are nonpolitical, objective, and research-based information.
- It provides practical, problem-oriented education for people of all ages. It is designated to take the knowledge of the university to those persons who do not or cannot participate in the formal classroom instruction of the university.
- It utilizes research from university, government, and other sources to help people make their own decisions.
- More than a million volunteers help multiply the impact of the Extension professional staff.
- It dispenses no funds to the public.
- It is not a regulatory agency, but it does inform people of regulations and of their options in meeting them.
- Local programs are developed and carried out in full recognition of national problems and goals.
- The Extension staff educates people through personal contacts, meetings, demonstrations, and the mass media.
- Extension has the built-in flexibility to adjust its programs and subject matter to meet new needs. Activities shift from year to year as citizen groups and Extension workers close to the problems advise changes.

Oklahoma State University, in compliance with Title VI and VII of the Civil Rights Act of 1964, Executive Order 11246 as amended, Title IX of the Education Amendments of 1972, Americans with Disabilities Act of 1990, and other federal laws and regulations, does not discriminate on the basis of race, color, national origin, gender, age, religion, disability, or status as a veteran in any of its policies, practices, or procedures. This includes but is not limited to admissions, employment, financial aid, and educational services.

Issued in furtherance of Cooperative Extension work, acts of May 8 and June 30, 1914, in cooperation with the U.S. Department of Agriculture, Robert E. Whitson, Director of Cooperative Extension Service, Oklahoma State University, Stillwater, Oklahoma. This publication is printed and issued by Oklahoma State University as authorized by the Vice President, Dean, and Director of the Division of Agricultural Sciences and Natural Resources and has been prepared and distributed at a cost of 20 cents per copy. 1003