



Center for Tropical and Subtropical Aquaculture

The Oceanic Institute

Makapu'u Point

Waimanalo, HI 96795

(808) 259-7951

fax (808) 259-8395

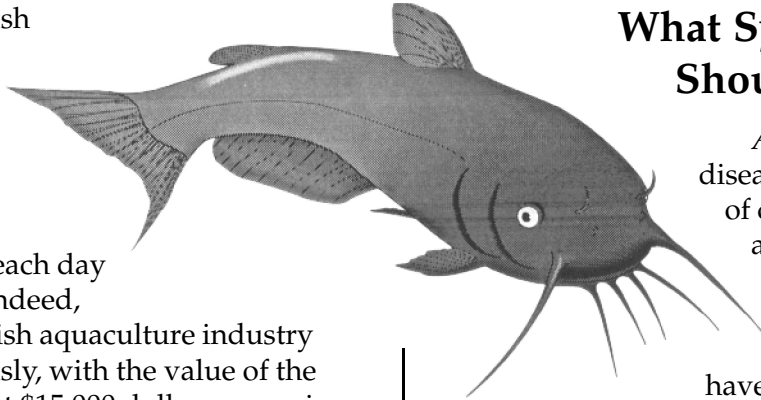
CTSA Publication No. 122

M a y 1 9 9 6

Bacterial Diseases in Chinese Catfish

The Chinese catfish (*Clarias fuscus*) is prized by many consumers as a fresh and flavorful alternative to the numerous varieties of saltwater fish caught each day in Hawaiian waters. Indeed, Hawaii's Chinese catfish aquaculture industry has grown tremendously, with the value of the crop jumping from just \$15,000 dollars a year in 1984 to approximately \$400,000 dollars per year just ten years later (industry figures courtesy of the Aquaculture Development Program, State of Hawaii Department of Land and Natural Resources). Despite this overall growth in catfish production, some Chinese catfish farms in Hawaii have suffered significant economic losses due to the periodic outbreak of bacterial disease that increase fish mortality. While scientists have made important strides in understanding and combatting these bacterial ailments in the past three years, more research is needed to ensure the continued viability of this exciting and expanding aquaculture crop in Hawaii and other parts of the world.

Diagnostic laboratory evaluations have revealed three bacterial agents thought to be the primary cause of disease in Chinese catfish: *Aeromonas hydrophila*, *Edwardsiella tarda* and a yet-to-be classified variety of myxobacteria. *A. hydrophila* and *E. tarda* are thought to be the causative agents of systemic infections in Chinese catfish.



What Symptoms Should I look for?

Aeromonas hydrophila disease can result in a variety of changes in the appearance of Chinese catfish. Affected fish are usually dark grey to black in color, may have small red sores on the body, a swollen abdomen or swelling on one or both sides of the body just behind the head (over the lateral lobes of the anterior kidney). Large, open sores on the body are also a common physical abnormality associated with *A. hydrophila*. Chinese catfish with *Edwardsiella tarda* disease frequently have large open sores that extend deep into the body. Swelling over the anterior kidney and the abdomen is also seen in fish suffering from *E. tarda*.

Infections resulting from a myxobacteria cause a discoloration and sloughing of skin, fins, and whiskers. Scientists studying these animals believe that the onset of these symptoms often follows some trauma (or a combination of traumas) to the creature's skin, such as an ectoparasite infection (e.g. *Gyrodactylus sp.*), a rapid drop in water temperature, or too much handling and manipulation of the catfish by the farmer.

Treatments

While certain medicated feeds used to treat bacterial diseases in other animals are also successful in healing similar infections in Chinese catfish, it is currently illegal to use these medications in catfish sold for human consumption in Hawaii. Moreover, the benefits of these medications are often temporary, and mortalities often return to previous levels if their use is discontinued. For these reasons, researchers have generally moved away from the use of antibiotics as a cure to bacterial infections in Chinese catfish and instead have sought to develop preventative methods to combat these illnesses.

In general, scientists have found that water quality does not appear to be a contributing variable to bacterial disease in these animals. However, manipulating other environmental factors, such as water depth, seems to yield some positive results in stopping these bacterial ailments from becoming a problem. At one catfish growout site, the use of a shallower tank dramatically reduced the incidence and prevalence of infections. Researchers speculate this overall decrease in disease levels is linked to the reduction in the amount of work needed for the fish at a shallower depth to reach the surface in order to breathe, giving them more energy to fight infections.

Financial support for this work was provided by the Center for Tropical and Subtropical Aquaculture through a grant from the United States Department of Agriculture (USDA grant #94-38500-0065). Partial support was provided by the Aquaculture Development Program, Hawaii Department of Land and Natural Resources (contract #34096). Production support was provided by the University of Hawaii Sea Grant College Program (SOEST), under Institutional Grant No. NA36RG0507. The views expressed herein are those of the author and do not necessarily reflect the views of USDA, CTSA, NOAA or any of its subagencies. UNIHI-SEAGRANT-FS-96-01.

New Research

Scientists working for the University of Hawaii are currently trying to boost the immune system of Chinese catfish through the development of a vaccine. Initial studies with *Aeromonas hydrophilia* have found that animals inoculated with a formulin killed preparation of the bacteria and boosted at 30 days following the initial vaccination, showed significantly higher rates of survival when later exposed to known lethal doses of *A. hydrophila*.

Where should I turn for help?

If your Chinese catfish crop is experiencing any of the external sores or other symptoms mentioned above, please contact one of the following groups for help:

- Aquaculture Development Program at Anuenue Fisheries Research Center
1039 Sand Island Parkway
Honolulu, Hawaii 96819-4347
(808) 845- 9561 Phone
(808) 845- 4334 Fax
- The University of Hawaii Sea Grant Extension Service
1000 Pope Road, MSB 226
Honolulu, Hawaii 96822
(808) 956-8191 Phone
(808) 956- 2858 Fax